



Headlines
Craniofacial Support
No 8
Saethre- Chotzen Syndrome
February 2004

Reg Charity No 1058461
www.headlines.org.uk

What is Saethre-Chotzen syndrome?

Saethre-Chotzen syndrome has only been recognised as a distinct entity for 20 years, although it has existed for much longer. In fact it was described independently by Saethre and Chotzen in the early 1930's. The reason that it took so long for these reports to be recognised as the same condition is because there are very variable features in affected individuals.

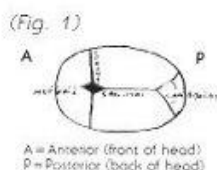
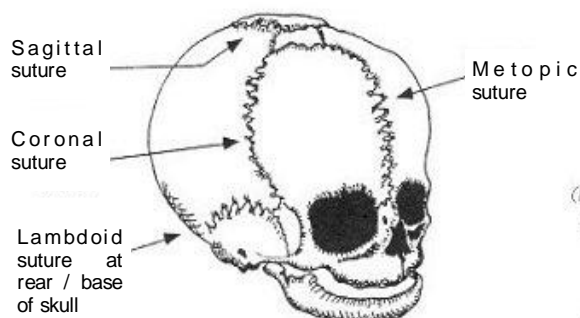
These differences in affected individuals is important in understanding the difficulties in predicting anomalies which may occur. It is now known that Saethre-Chotzen is caused by mutations in the TWIST gene. (For more details see Headlines Leaflet 'What causes Craniosynostosis'). The variability of presentation may still make diagnosis difficult.

What are the common features?

Previous reports of the condition have emphasized the following anomalies: craniosynostosis, droopy eyelids, short fingers which may be joined together by the skin, and broad big toes with other toes short, and the fusing of the bones of the neck. However, it can be difficult to be sure whether someone is affected, as the range of involvement can be from none of the above to all of them! This may be complicated further by marked degrees in the severity of each affected site. The condition as it may affect each of these sites will be considered in turn.

How is the condition treated?

The craniosynostosis affects the coronal sutures, usually both, producing a short wide head (brachycephaly). Occasionally only one side is affected and this produces an asymmetrical head (plagiocephaly). These abnormal-shaped heads can be corrected, but there are two different reasons for doing this. Firstly, the skull



may not grow as quickly as the brain and lead to raised pressure around the brain. If this happens then an operation is usually advised to make the skull bigger, to allow the pressure around the brain to be normal, and so the brain can grow. Secondly, the appearance may need to be improved surgically, especially in the unicoronal cases. There are times when operative intervention is advised for both of these reasons.

The **droopy eyelids** (or ptosis), usually present no problems but can on occasion be so severe as to impair upward gaze. This may require surgical correction which is a relatively minor plastic surgery procedure. A squint may also be associated with the condition requiring ophthalmological care.

The **joining of the bones** (vertebrae) in the neck, if it occurs, usually only affects the two adjacent vertebrae. These fusions occur after birth during childhood. Currently, there are no known adverse effects directly resulting from these but care must be taken during anaesthetics and radiographs may be taken prior to surgery.

The **short fingers** and the **joining of the fingers** (syndactyly) rarely cause any problems. The joining, if it occurs, often only affects the base of the fingers and is unlikely to affect function of the hand. There are no reports of anyone with the condition requiring surgery for their hands. The growth of the bones of the hands are often delayed during childhood but again there are no clinical implications resulting from this.

The **feet** may have broad toes, as occasionally the bones at the ends of the toes attempt to duplicate themselves. The big toe is most commonly affected and this does not present any problems clinically. The children walk at the normal time and should have no difficulties with footwear.

Other joints have on occasion been reported to be affected but these must be extremely rare and may just reflect uncertainty regarding the diagnosis. The ears too have been reported as having a higher incidence of minor anomalies but the significance of this remains unclear.

In conclusion, a variety of different sites may have anomalies and each of these can vary in degree of severity. A list of some of the previous reports is given but it has to be emphasized that most reports relate to only a few cases and making generalisations from these is difficult.

Bibliography

Saethre-Chotzen syndrome: A broad and variable pattern of skeletal malformations Friedman, J.M., Hanson, J.W., Graham, CB., Smith, D.W.. J Pediatr. 1977; 91: 929-933.

Saethre-Chotzen syndrome Reardon, W., Winter, R.M.. J Med Genet., 1994; 31: 393-397.

The Saethre-Chotzen syndrome. Birth Defects Pontke, O.A., Cohen, M.M., Witkop, C.J. et al.. 1975: 11: 190-223

This leaflet has been written by Peter Anderson, Craniofacial Fellow, Great Ormond Street Hospital for Children NHS Trust.

Revised by Headlines in February 2004, to add gene information.

**Other leaflets are available from
Headlines-Craniofacial Support
Please contact Group Administrator
Gil Ruff on 01454 850557
for details on how to obtain copies**