



# **Headlines**

## **Craniofacial Support**

### **No 6**

# **Crouzon Syndrome**

**Reg Charity No 1058461**  
**[www.headlines.org.uk](http://www.headlines.org.uk)**

## Introduction

Crouzon syndrome is an inherited syndrome of *craniofacial dysmorphology*, or abnormal craniofacial appearance, which was originally described in 1912 and is now well recognized. It is thought to occur in 1/25,000 births.

Children who have Crouzon syndrome have a range of problems of variable severity, from mild facial symptoms causing a primarily cosmetic concern, to severe symptoms affecting breathing, feeding, vision and brain development.

The child with Crouzon syndrome usually enters a coordinated programme of care involving many different clinical specialities integrating their various expertise, which often continues from birth to the later teenage years. In addition, there is an on-going programme of research into many aspects of Crouzon and its related syndromes, to constantly investigate and update the services that the specialist team provide.

## The child with Crouzon syndrome

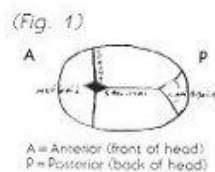
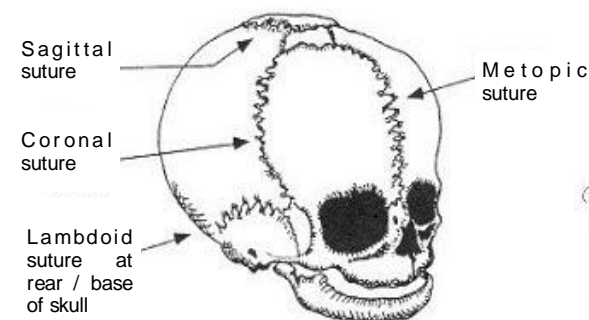
Crouzon syndrome predominantly affects the appearance of the head and face.

The **skull**, or *calvarium*, is made up of flat plate-like cranial bones which are connected by seam-like joints, or cranial *sutures*. There are many such sutures, but the most clinically important are

- the *metopic* and *sagittal* sutures running from front to back and interrupted by the *anterior fontanelle* (soft spot),
- the *coronal* sutures running from side to side from the *anterior fontanelle* to the temple and
- the *lambdoidal* suture running from the *posterior fontanelle* to the back of the base of the skull

Neighbouring cranial bones are thus mobile against each other, and this first allows normal birth, and then growth of the brain inside the skull without restriction.

During normal childhood and into adulthood, the sutures fuse, becoming bone in a seemingly pre-programmed fashion, protecting the brain within. The growth of the face and skull are, of course, closely integrated, and facial bones are also joined by sutures which slowly fuse throughout life.



In Crouzon syndrome, either or both of the skull and face may be affected. In the skull, the cranial sutures may fuse prematurely, and this is called *craniostenosis* or *craniosynostosis*. This alters the pattern of skull growth, and thus the shape of the skull, sometimes with consequences for the developing brain. There are characteristic skull shapes depending upon the pattern of sutural fusion. Crouzon syndrome may involve any combination of cranial sutures, most commonly including the coronal and sagittal sutures. Common

terms for the resulting head shapes are *brachycephaly* – giving a flat forehead, *scaphocephaly* – a boat shaped skull and *turricephaly* – tower shaped skull; and these may result in different pressures on the growing brain.

Craniosynostosis usually begins during pregnancy or the first year of life and is complete by three years of age. Raised *intracranial pressure* may become a clinical concern.

In the **face**, the commonest features are a regressed mid-face and shallow *orbits* (eye sockets), which may be present at birth or become more evident as the childhood progresses. The arrangement of the **teeth**, or *dentition*, is also affected, and this requires specialist orthodontic care, which is dependent on good dental care at home. Rarely, there may be **palate** problems. Seen from the side the face has a concave appearance, and the shallow orbits result in prominent eyeballs or *proptosis*.

## Clinical problems and programme of care

The child with Crouzon syndrome may thus have a range of clinical problems. Although the head shape is often the most striking initial feature, from the outset the major concerns are the ease of breathing and potential feeding problems.

The regressed mid-face, or *maxillary hypoplasia*, results in a small larynx and pharynx behind the nose and

mouth. This restricts the passage of air into the *trachea* (windpipe) and lungs, and causes respiratory distress, particularly at night when snoring and snuffling can interrupt sleep. The degree of airway obstruction and quality of sleep is assessed by a 'sleep study', and if necessary, treatment takes the form of CPAP (Continuous Positive Air Pressure) devices at home or surgical intervention. Similarly, the passage of food is restricted and regurgitation may result in aspiration of food into the lungs.

The shallow orbits and proptosis may threaten the cornea, or surface of the eyeball, with *exposure keratitis*, and surgical measures may become necessary to protect the exposed eyes. All children have regular ophthalmic review, as other ocular problems may uncommonly occur. Ear, nose and throat (ENT) follow-up is also recommended, as some children have hearing difficulties, and grommets may be advised to treat chronic infections and improve hearing. The common surgical approaches are given in the table overleaf.

The abnormal skull shape may require surgery to protect the constricted brain and help relieve raised *intracranial pressure*, which is most commonly revealed by headaches or visual changes identified by the ophthalmologist. The aim of this surgery called *cranioplasty* is to provide a more normal head shape and increase the volume of the skull. Examples of cranioplasty include *frontal* and *fronto-orbital advancement*, *vault expansion* and *frontal* or *posterior remodelling*. For more information, see Headlines leaflet **Craniofacial Surgery**. Pressure is thus taken off the growing brain. Another surgical method of reducing intracranial pressure is to insert a *ventriculoperitoneal shunt*, and either or both may be used at different times during childhood, as the skull shape of Crouzon syndrome may be only one of many contributing factors to raised intracranial pressure.

At the current time it is impossible to predict how the skull and face abnormalities will progress as the child grows, and surgical decisions are made in the light of circumstances as they arise. In addition, 'variability of expression' characterizes the condition – some children may have mid-face problems only, others may have craniosynostosis only, whilst others may have severe craniosynostosis and mid-face regression together. Surgery may be indicated for cosmetic reasons only, or for the more serious conditions described.

Any surgical intervention is closely planned with all the teams involved. The surgical side of the craniofacial team usually consists of the craniofacial surgeon, neurosurgeon, ENT and ophthalmic surgeons. In addition the orthodontist co-ordinates very closely with the surgical teams. The team is made complete by the geneticist, psychologist, speech and language therapist, respiratory care specialist, and specialist nursing staff.

### **Non-surgical aspects**

Developmental delay in the absence of raised intracranial pressure in Crouzon syndrome is rare. The psychology and language therapy teams have many means of identifying and treating developmental delay early, and their important role in the overall care of the child is emphasised.

Though many new cases are spontaneous, Crouzon syndrome can run in families. When this happens it does so in a 'dominant' manner. The genetic basis of the syndrome is one of the recent research discoveries. Although the inheritance is 'dominant', it must be remembered that the expression of the disease in the child is variable, and most children of a Crouzon family will not be severely affected. The geneticist will advise about risk in subsequent generations of a family.

## Summary

Crouzon syndrome is an inherited syndrome affecting craniofacial growth and development. The care of the child with Crouzon syndrome is multi-disciplinary, involving the coordinated expertise of many clinical teams. Surgical care is staged throughout life from infancy to late adolescence, and may follow the following pattern as clinical circumstances arise.

Operation	Age	Indication
Cranioplasty	Infancy	Skull expansion and remodelling, for cosmetic benefit and to relieve intracranial pressure
Shunt surgery	Childhood	Neurosurgical operation to reduce intracranial pressure
Facial advancement	Childhood Adolescence	To protect the eyes, protect against breathing difficulty, and provide cosmetic benefit. Often preceded and followed by a programme of orthodontics
Choanal dilation Grommet insertion Bone anchored hearing aid	Childhood	ENT procedures to improve the airway, treat chronic ear infection, aid hearing
Squint surgery Tarsorrhaphy	Childhood	To correct ocular squint and improve vision. Tarsorrhaphy may be used to protect against exposure damage to the surface of the eye

## Further reading

**Assessment and Treatment of Craniosynostosis.** Thompson D, Jones B M, Hayward R D, Harkness W; British Journal of Hospital Medicine 1994, 52 (1); 17-24.

**Complications in Paediatric Craniofacial Surgery; an initial four year experience.** Jones B M, Jani P, Bingham R M, Mackersie A M, Hayward R; British Journal of Plastic Surgery 1992, 45, 225-231.

Written by Jonathan Britto, Craniofacial Research Fellow, Great Ormond Street Hospital for Children NHS Trust

**Other leaflets are available from  
Headlines-Craniofacial Support  
Please contact Group Administrator  
Gil Ruff on 01454 850557  
for details on how to obtain copies**